

Hemoptysis Cases

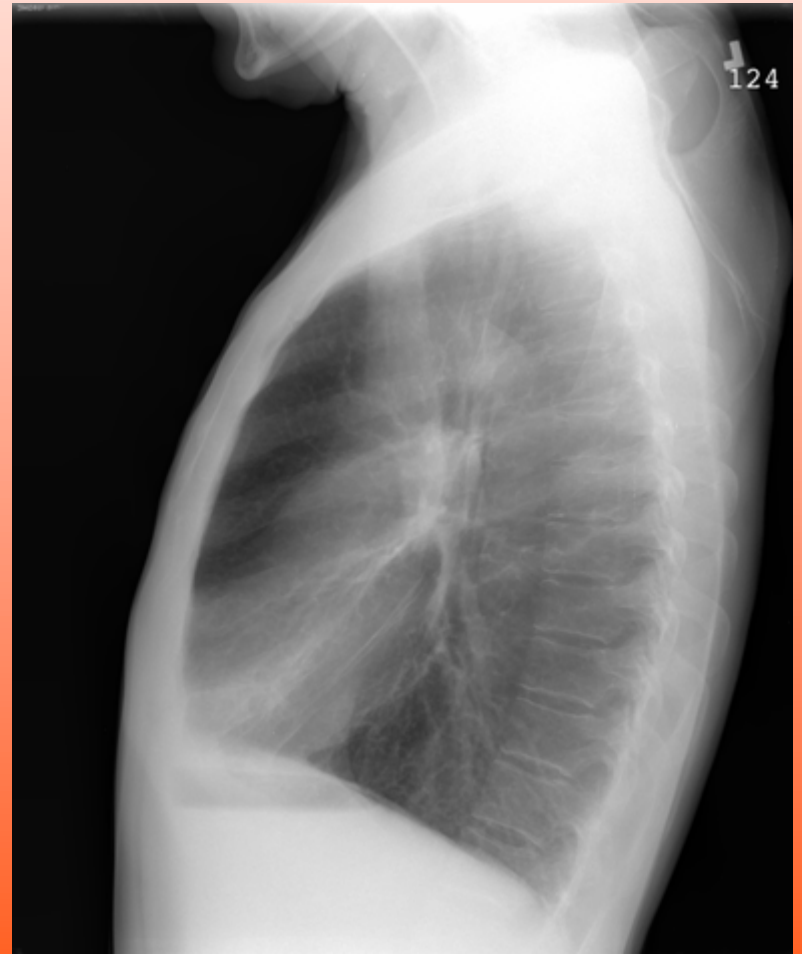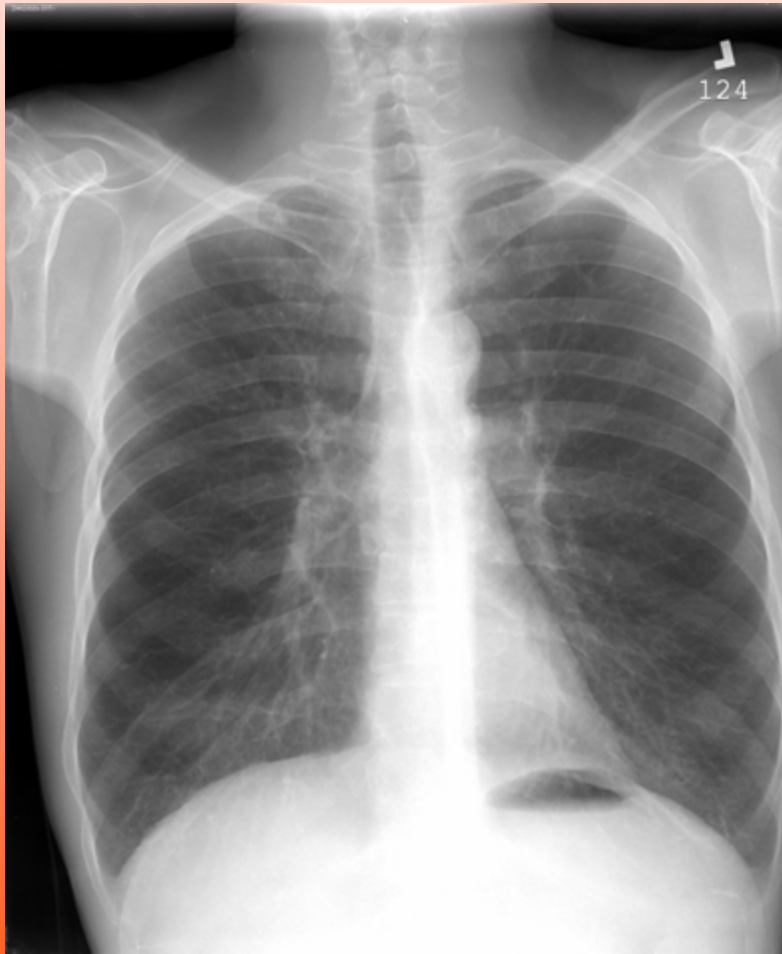
John W. Kreit, M.D.

Division of Pulmonary, Allergy,
and Critical Care Medicine

Case 1

- 73 yo M with >100 pack-year h/o smoking and a chronic, productive cough
- 2-week history of increased cough and sputum production accompanied by hemoptysis that varies from blood streaking to pure blood
- No fevers, chills, or increased dyspnea

Case 1



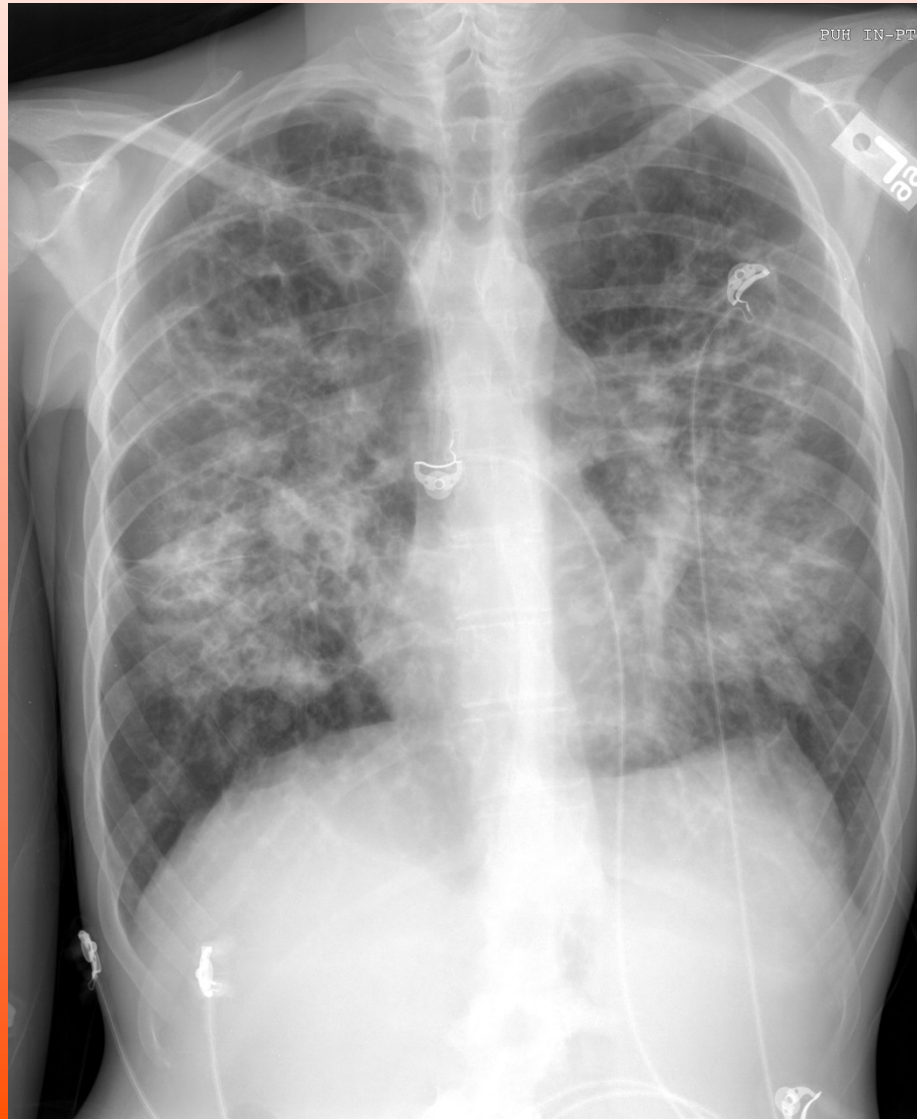What should be done next?

- A. Chest CT
- B. Bronchoscopy
- C. Treat for bronchitis and do additional testing only if the hemoptysis persists

Case 2

- 23 yo M with cystic fibrosis
- Several hours of hemoptysis
- Expecting several tablespoonsful of pure blood about every 5 minutes
- Estimates that he has expectorated enough blood to fill 3-4 coffee cups
- Mild increase in chronic dyspnea
- O₂ requirement has increased from 3 to 4 LPM

Case 2



What should be done next?

- A. Chest CT
- B. Chest CT angiography
- C. Bronchoscopy
- D. Intubation followed by bronchoscopy
- E. Bronchial artery embolization